

Efficacy of the Reduction Mammoplasty Measured by Infrared Thermography-MDbP 304

Sang Dal Lee, Seung Geun Lee, Woo Sang Ryu, Min Kuk Kim, Young Soon Jeon¹

Breast Center, MD Hospital, Seoul; ¹Ji Ann Rehabilitation Medicine, Seoul, Korea

Purpose: Gigantomastia is associated with several physical symptoms. Reduction mammoplasty can resolve discomfort, but an objective and quantitative analysis of the symptomatic relief associated with reduction mammoplasty is limited. Therefore, we evaluated the efficacy of reduction mammoplasty, as measured by the symptomatic relief using objective indicators. **Methods:** Between January and May 2009, patients who visited our clinic for gigantomastia were retrospectively evaluated, for neck, shoulder, and back pain. Fifteen subjects were enrolled in this study; they all underwent treatment by reduction mammoplasty, and presented neck and shoulder pain. The surface body temperature was measured at the cervical and thoracic areas, by infrared thermography (Iris-5000; Medcore, Seongnam, Korea). Infrared thermography was re-assessed in nine of 15 cases who returned for follow-up examinations 3 to 4 months after surgery. **Results:** The mean age of the group was 40.6 ± 10.3 years; the mean body mass index was 24.6 ± 2.1 kg/m². The average weight of the removed breast tissue after surgery was 616 ± 241.8 g on the right, and 603 ± 259.6 g on the left. On pre-, and post-operative infrared thermography, the average absolute value of the thoracic and cervical surface temperatures changed significantly ($p < 0.050$). **Conclusion:** We observed significant changes in the surface temperature in the cervical and thoracic areas by using an infrared thermography. Therefore, infrared thermography can be used to detect the relief of symptoms, due to heavy breasts, objectively and quantitatively.

Key Words: Gigantomastia, Mammoplasty, Thermography

INTRODUCTION

Gigantomastia is defined as an increase in breast tissue, not caused by an accident, tumor, hemorrhage, inflammation, or pregnancy, which interferes with physical activity. Gigantomastia is associated with a constellation of physical symptoms, including neck, back, and shoulder pain, grooving from the brassiere straps, and intertrigo. Further, gigantomastia is associated with psychosocial symptoms, such as mood disorder [1]. The surgical literature has many articles describing its techniques and aesthetic results of reduction mammoplasty. Reduction mammoplasty, regardless of the surgical method, can improve pain and discomfort, cosmetic appeal, and social, physical, and psychologically well-being. While the postoperative outcomes from reduction mammoplasty can vary for each patient, an objective and quantitative analysis of symptomatic relief due to

reduction mammoplasty is limited.

Thermography uses an infrared camera to capture the temperature change of the skin, which can be observed as an increase or decrease in the bloodstream, inflammation, and the dysfunction of nerves. The first use of diagnostic infrared thermography was performed in 1957 by Lawson, who discovered that the skin temperature over the tumor of the breast was higher than that of the normal tissue [2]. However, the use of this technology for medical applications has not been clearly demonstrated due to poor performance and high cost of infrared cameras. Over the past 10 years, there has been a resurgence of interest in the medical application of infrared thermography, due to improvements in infrared camera technology and in new algorithms. Improvements in infrared sensors, image processing, and analysis techniques have allowed a more accurate analysis of thermal information for the physiologic reaction of pain, and infrared thermography has been used in the diagnosis of musculoskeletal pain [3-7]. Infrared thermography has several advantages. It is simple to use, non-invasive, and employs objective biological indicators of pain-related responses in the musculoskeletal system [6]. The purpose of our study was to

Correspondence: Sang Dal Lee

Breast Center, MD Hospital, 832 Seolleung-ro, Gangnam-gu, Seoul 135-954, Korea

Tel: +82-2-542-0081, Fax: +82-2-542-4443, E-mail: dahl65@hanmail.net

Received: December 26, 2014 **Revised:** March 11, 2015 **Accepted:** April 20, 2015

evaluate the efficacy of reduction mammoplasty, as measured by the symptom relief using an objective indicators.

METHODS

Between January and May 2009, patients who visited our clinic for gigantomastia were evaluated, retrospectively, for breast, neck, shoulder, back pain, hand numbness, and headaches. Fifteen subjects were enrolled in this study, and they all underwent reduction mammoplasty, and presented neck and shoulder pains. The spine balance and curvature was measured by a spinal X-ray. Due to adaptation, patients were exposed to 23°C measuring space for 15 minutes, which was blocked from ambient light and heat. The surface body temperature was measured at the cervical and thoracic areas, by infrared thermography (Iris-5000; Medcore, Seongnam, Korea). Nine patients had post-surgical follow-up examinations and the infrared thermography readings were taken from the same locations 3 to 4 months after surgery. These readings were then compared with the baseline operative data. Pre-, and postoperative changes in body surface temperature were assessed with paired t-test, and $p < 0.05$ was considered statistically significant. Height, body weight, age, body mass index (BMI), and the weight of the removed breast were analyzed with multiple regression tests for the effect of the change in the body surface temperature. SPSS version 17.0 (SPSS Inc., Chicago, USA) was used for all statistical analyses.

Table 1. Clinical features of case

Case	Age (yr)	Ht (cm)	Wt (kg)	BMI (kg/m ²)	Pain			Remove amount (g)	
					Cervix	Shoulder	Back	Rt	Lt
1	27	170	63	21.8	+	+	+	320	335
2	28	167	65	23.3	+	+	+	555	565
3	29	158	60	24.0	+	+	+	425	325
4	29	162	67	25.5	+	+	+	840	905
5	32	162	90	34.3	+	+	+	1,740	1,625
6	33	164	75	27.9	+	+	+	730	750
7	36	159	65	25.7	+	+	+	725	680
8	37	155	58	24.1	-	+	-	975	1,035
9	45	153	48	20.5	+	+	+	160	180
10	45	154	57	24.0	+	+	+	665	585
11	47	155	52	21.6	+	+	+	380	370
12	48	150	47	20.9	-	+	-	250	230
13	52	155	59	24.7	+	+	+	545	525
14	53	162	63	24.0	+	+	+	440	390
15	53	157	65	26.4	+	+	+	485	540

Ht = height; Wt = weight; BMI = body mass index; Rt = right; Lt = left.

RESULTS

The mean age of the group was 40.6 ± 10.3 years, and the mean BMI was 24.6 ± 2.1 kg/m². In all cases, there was pain in the shoulder region. Further, cervical, and back pain were also reported, except in two cases (Table 1). The average weight of the breast tissue removed by surgery was 616 ± 241.8 g from the right, 603 ± 259.6 g from the left. The preoperative whole spine X-ray findings revealed all cases did not fit the balance and the curvature. Age, height, weight, BMI and weight of the removed breast tissue did not significantly correlate with the body surface temperature and the change in body surface temperature ($p > 0.050$). On pre-, and postoperative infrared thermography, the average cervical surface temperature had a meaningful change, which was 1.9°C on the right ($p = 0.042$), and 1.5°C on the left side ($p = 0.020$). However, average thoracic surface temperature did not change significantly (1.0°C, right, $p = 0.210$; 1.2°C, left, $p = 0.188$) (Table 2) (Figure 1).

Table 2. Statistical analysis of thermographic findings

Site	Pre-op. (°C) (Mean ± SD)	Post-op. (°C) (Mean ± SD)	Difference (°C) (Mean ± SD)	p-value
Cervix				
Rt.	29.3 ± 2.1	27.4 ± 1.2	1.9 ± 2.4	0.042
Lt.	29.2 ± 2.0	27.7 ± 1.2	1.5 ± 1.6	0.020
Thorax				
Rt.	28.4 ± 1.9	27.4 ± 1.4	1.0 ± 2.1	0.210
Lt.	28.7 ± 1.6	27.5 ± 1.7	1.2 ± 2.4	0.188

Pre-op = pre-operation; Post-op = post-operation; Rt = right; Lt = left.

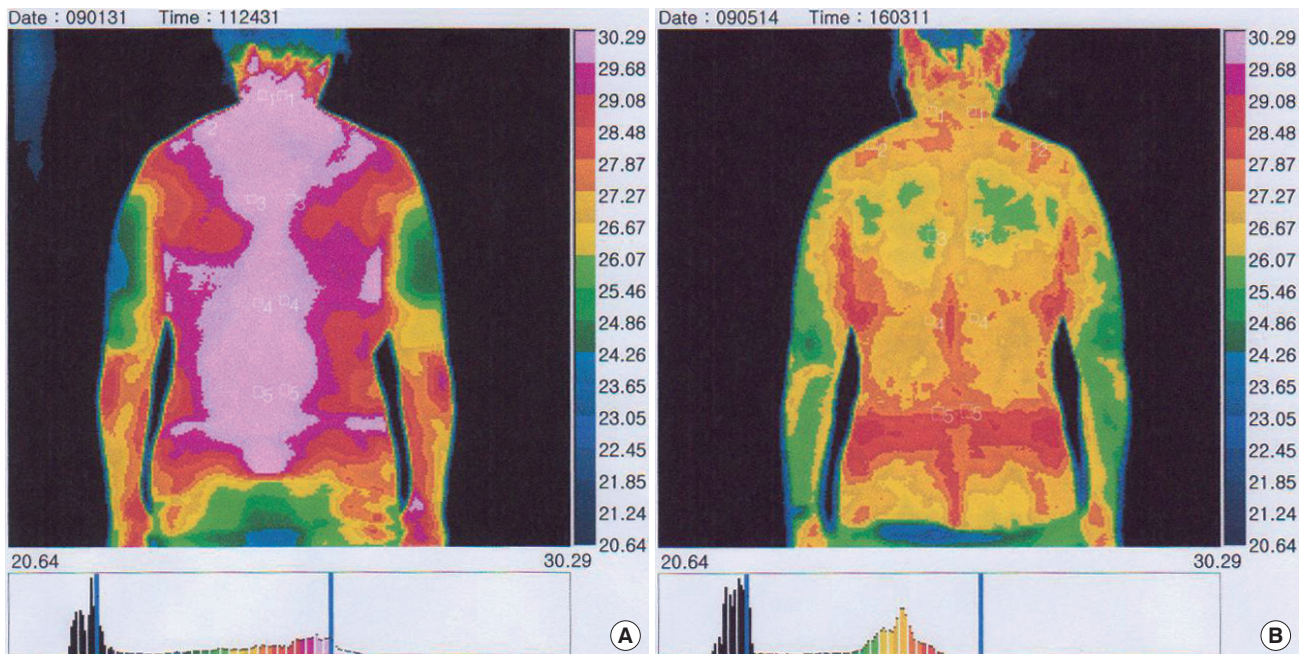


Figure 1. Changes of skin temperature of cervical and thoracic zones (A). Preoperative infrared thermographic image (B). Postoperative thermographic image.

Table 3. Thermographic findings

Case	Preoperation (°C)				Postoperation (°C)			
	Cervix		Thorax		Cervix		Thorax	
	Rt	Lt	Rt	Lt	Rt	Lt	Rt	Lt
1	31.0	31.0	28.4	28.3	27.5	28.9	28.8	29.4
2	27.8	26.8	26.9	29.3	25.1	25.4	25.8	25.3
3	31.5	31.2	28.9	29.0	28.9	29.1	27.8	27.2
4	29.0	27.9	30.9	31.0	27.9	27.6	28.2	28.1
5	31.2	31.0	30.3	30.1	27.0	27.3	26.0	26.1
6	29.3	29.7	27.6	27.4	27.5	28.8	29.1	30.2
7	30.9	30.4	30.0	30.2	27.5	27.1	28.6	28.3
8	25.1	25.5	25.2	26.4	29.0	27.0	27.5	27.9
9	27.8	29.0	27.4	26.7	26.2	27.8	25.3	25.5

Rt = right; Lt = left.

Table 4. Statistical analysis on the range of change in the temperature

Site	Difference (°C) (Mean ± SD)	<i>p</i> -value
Cervix		
Rt.	2.8 ± 1.0	0.001
Lt.	1.8 ± 1.1	0.001
Thorax		
Rt.	1.6 ± 1.6	0.021
Lt.	1.7 ± 2.0	0.031

Rt = right; Lt = left.

However, in most patients, cervical and thoracic surface temperatures, after surgery, were lower than before, but in some cases, they were

higher (Table 3). Therefore, we performed statistical analyses focused on the changes in both directions, and observed statistically significant changes in both lesions ($p < 0.050$) (Table 4).

DISCUSSION

Human posture in the erect position is maintained by ligamentous and muscular support. The center of gravity of the human body in profile passes from the external auditory meatus through the odontoid process, which is slightly posterior to the center of the knee, and to a point slightly anterior to that of the lateral malleolus [8]. Exces-

sively large breasts can affect posture and the normal axis of gravity through the body, by increasing the cervical lordosis. The resulting postural change is not only fatiguing but also promotes pain by increasing the muscle tension in the extensor muscles of the neck. Excessively large breasts also lead to thoracic kyphosis and downward rotation of the scapula with tension traction on the attachment of the levator scapulae muscle, which leads to myofasciitis at the attachment site [9]. In addition, heavy breasts lead to gradual weakening of the trapezius muscles that are responsible for stabilizing the surrounding structures. These changes in anatomical posture, due to several symptoms caused by heavy breasts, consequently cause an imbalance in the body, and thus, pain [8,10].

In addition to the cosmetic effect of reduction mammoplasty, there are reports of increased functional activity and pain relief after surgery [11,12]. These studies contribute to our understanding of the symptoms associated with heavy breasts and to our knowledge of the physical changes after surgery. However, most studies were retrospective study, and did not use diagnostic methods, which allow for the objective interpretation of results [13-15]. Sequential infrared thermographic imaging can be helpful in determining and tracking the treatment effectiveness because it can be recorded on both sides of an asymmetric area or the surrounding temperature is high, compared to lesions in part [16,17].

Thermographic measurement of skin temperature can be affected by the external environment, measurement time, and measuring interval. These affects may be mitigated by maintaining a constant temperature, by preventing the exchange of ambient light and heat at the point of imaging and keeping equilibrium with the skin and the surrounding measuring site. For example, results can differ between readings in the morning and afternoon on the same day, but most of these differences are less than 0.5°C, which does not have any reported clinical significance [5,18]. We performed the exam in an enclosed space, with external light blocked, from 1:00 PM to 4:00 PM, to hold imaging conditions as constant as possible for each patient.

The pathogenesis of symptoms, due to heavy breast include structural changes of the spine and spinal muscles that leads to inflammation and local change in metabolism. As a result, the skin temperature of these lesions would expected to be higher than normal, which was observed on thermographic imaging. In contrast, before the surgery, the skin temperature of a specific area can be lower than the tempera-

ture after the surgery. Ammer et al. [19] explained this phenomenon as pain creating a higher temperature caused by inflammation. However, it can create lower skin temperature, which is caused by stimulating the sympathetic nervous system. It leads to vasoconstriction and deteriorating blood circulation to the surface of the skin. Thus, pain may increase or decrease the surface temperature of the skin, and this is believed to be responsible for the dispute regarding the analysis of thermography results.

In this study, the average pre-, and postoperative infrared thermography readings of the cervical surface, with reference to the Ammer et al. study [19], showed a meaningful change, which was 1.9°C on the right ($p = 0.042$), and 1.5°C on the left side ($p = 0.020$). However, the average thoracic surface temperature did not show a statistically significant change. As shown in Table 3, in some cases, the skin temperature was rising after the surgery, which serves to compensate for the temperature difference in the statistical analysis. Therefore, as done by Ammer et al. study [19], we performed a statistical analysis on the change in the temperature, rather than an increase or decrease in temperature, and the result was a statistically significant change in the body surface temperature (Table 4).

On the thermographic exam, the body surface temperature of obese patients was lower than the temperature of patients with normal body weight because adipose tissue has low thermal conductivity [20]. The average BMI of the enrolled patients was 24.6 kg/m². Five of the 15 patients were classified as mild obese (BMI >25 kg/m²). The severity of obesity can affect the imaging results because the central axis of the body is altered and joints are deformed, which mimic the symptoms of heavy breasts. For this reason, Freire et al. [21] also excluded the patient with BMI of 30 or higher in the study of functional activity and the degree of pain reduction after a reduction mammoplasty. In our study, one patient who was severely obese (BMI >30 kg/m²) was excluded from the analysis of the infrared thermographic exam, because the errors caused by obesity could not be disambiguated from the symptoms of heavy breasts.

After breast reduction, long-term adaptation will be necessary to change the skeletal structure by the resolution of overload. Mizgala and MacKenzie [22] also reported pain reduction in patients, but 16% of patients still remained in mild or moderate pain. The persistent pain after surgery was caused by the change of skeletal structure, which did not improve in a short postoperative time, and the constant

tension of the muscles, due to the support of an already transformed skeletal structure.

The limitations of this study are that the number of subjects was small and the correlations of postsurgical thermography results with clinical symptoms and changes in posture were not analyzed. Accordingly, if the correlations of thermography results with clinical symptoms and changes in posture are analyzed in studies with more patients in the future, we believe that thermography will be useful to quantitatively and objectively evaluate the effect of mammoplasty.

CONFLICT OF INTEREST

The authors declare that they have no competing interests.

REFERENCES

1. Lee SD. Reduction Mammoplasty-100 Cases by Single Surgeon-MDBP302. *J Korean Surg Soc* 2006;71:95-9.
2. Lawson R. Thermography; a new tool in the investigation of breast lesions. *Can Serv Med J* 1957;8:517-24.
3. Bertmaring I, Babski-Reeves K, Nussbaum MA. Infrared imaging of the anterior deltoid during overhead static exertions. *Ergonomics* 2008;51:1606-19.
4. Herry CL, Frize M. Quantitative assessment of pain-related thermal dysfunction through clinical digital infrared thermal imaging. *Biomed Eng Online* 2004;3:19.
5. Jiang LJ, Ng EY, Yeo AC, Wu S, Pan F, Yau WY, et al. A perspective on medical infrared imaging. *J Med Eng Technol* 2005;29:257-67.
6. Meeker WC, Gahlinger PM. Neuromusculoskeletal thermography: a valuable diagnostic tool? *J Manipulative Physiol Ther* 1986;9:257-66.
7. Mir y Mir L, Planes AB, Caragol SM. The value of preoperative thermography in patients undergoing reduction mammoplasty and mastopexy. *Ann Plast Surg* 1979;3:504-15.
8. Letterman G, Schurter M. The effects of mammary hypertrophy on the skeletal system. *Ann Plast Surg* 1980;5:425-31.
9. Cailliet R. Pain in the neck and arm. Diagnosis by history and examination. *Calif Med* 1968;108:99-103.
10. Kaye BL. Neurologic changes with excessively large breasts. *South Med J* 1972;65:177-80.
11. Chadbourne EB, Zhang S, Gordon MJ, Ro EY, Ross SD, Schnur PL, et al. Clinical outcomes in reduction mammoplasty: a systematic review and meta-analysis of published studies. *Mayo Clin Proc* 2001;76:503-10.
12. Miller BJ, Morris SF, Sigurdson LL, Bendor-Samuel RL, Brennan M, Davis G, et al. Prospective study of outcomes after reduction mammoplasty. *Plast Reconstr Surg* 2005;115:1025-31; discussion 32-3.
13. Hughes LA, Mahoney JL. Patient satisfaction with reduction mammoplasty: an early survey. *Aesthetic Plast Surg* 1993;17:345-9.
14. Gonzalez F, Walton RL, Shafer B, Matory WE Jr, Borah GL. Reduction mammoplasty improves symptoms of Gigantomastia. *Plast Reconstr Surg* 1993;91:1270-6.
15. Schnur PL, Schnur DP, Petty PM, Hanson TJ, Weaver AL. Reduction mammoplasty: an outcome study. *Plast Reconstr Surg* 1997;100:875-83.
16. Swerdlow B, Dieter JN. An evaluation of the sensitivity and specificity of medical thermography for the documentation of myofascial trigger points. *Pain* 1992;48:205-13.
17. Hakguder A, Birtane M, Gurcan S, Kokino S, Turan FN. Efficacy of low level laser therapy in myofascial pain syndrome: an algometric and thermographic evaluation. *Lasers Surg Med* 2003;33:339-43.
18. Sherman RA, Barja RH, Bruno GM. Thermographic correlates of chronic pain: analysis of 125 patients incorporating evaluations by a blind panel. *Arch Phys Med Rehabil* 1987;68:273-9.
19. Ammer K, Schartelmueller T, Melnizky P. Thermal imaging in acute herpes zoster or post-zoster neuralgia. *Skin Res Technol* 2001;7:219-22.
20. Savastano DM, Gorbach AM, Eden HS, Brady SM, Reynolds JC, Yanovski JA. Adiposity and human regional body temperature. *Am J Clin Nutr* 2009;90:1124-31.
21. Freire M, Neto MS, Garcia EB, Quaresma MR, Ferreira LM. Functional capacity and postural pain outcomes after reduction mammoplasty. *Plast Reconstr Surg* 2007;119:1149-56; discussion 57-8.
22. Mizgala CL, MacKenzie KM. Breast reduction outcome study. *Ann Plast Surg* 2000;44:125-33; discussion 133-4.